




Contents lists available at ScienceDirect

## The Journal of Foot &amp; Ankle Surgery

journal homepage: www.jfas.org



## Original Research

## Observed Changes in Radiographic Measurements of the First Ray after Frontal Plane Rotation of the First Metatarsal in a Cadaveric Foot Model

Paul Dayton, DPM, MS, FACFAS<sup>1</sup>, Mindi Feilmeier, DPM, FACFAS<sup>2</sup>, Jordan Hirschi, BS<sup>2</sup>, Merrell Kauwe, BS<sup>2</sup>, John S.K. Kauwe, PhD<sup>3</sup><sup>1</sup>Unity Point Health, Trinity Regional Medical Center, Des Moines University College of Podiatric Medicine and Surgery, Fort Dodge, IA<sup>2</sup>Des Moines University College of Podiatric Medicine and Surgery, Des Moines, IA<sup>3</sup>Departments of Biology and Neuroscience, Brigham Young University, Provo, UT

## ARTICLE INFO

Level of Clinical Evidence: 5

## Keywords:

hallux valgus  
intermetatarsal angle  
metatarsal phalangeal joint  
sesamoid position

## ABSTRACT

We observed the changes in the angular measurements commonly used in the evaluation of the first metatarsal and first metatarsophalangeal joint in cadaveric specimens before and after frontal plane rotation of the first metatarsal. Measurements of the first and second intermetatarsal angle (IMA), hallux abductus angle, proximal articular set angle, and tibial sesamoid position (TSP) were taken after varying degrees of varus and valgus rotation of the first metatarsal. Standard dorsoplantar radiographs were taken at 0°, 10°, 20°, and 30° of valgus rotation of the first metatarsal and repeated at 10°, 20°, and 30° varus rotation of the first metatarsal. The data were analyzed using a mixed linear model to compare the change in each angle measurement over the range of valgus and varus rotation. The change in the TSP was significant in both valgus and varus rotations ( $p = .0004$  and  $p = .028$ , respectively), an increase in valgus rotation causing an increase in the TSP and an increase in varus rotation causing a decrease in TSP. The change in the IMA was significant compared with valgus rotation ( $p = .028$ ), showing that as the valgus rotation increased, the IMA also increased. However, compared with the varus rotation, the correlation was not significant ( $p = .18$ ). The proximal articular set angle and hallux abductus angle measurements, compared with metatarsal rotation, showed positive trends but were not statistically significant. From our results and a review of the published data, we have hypothesized that frontal plane rotation of the first metatarsal is an integral component of hallux abducto valgus pathologic features, specifically in relation to the TSP and IMA.

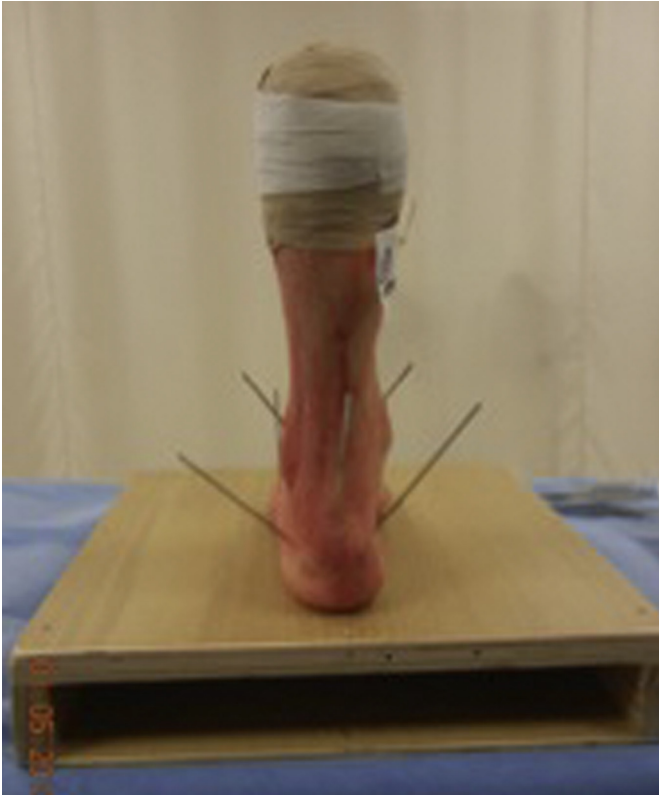
© 2014 by the American College of Foot and Ankle Surgeons. All rights reserved.

Rotation of the first metatarsal, as a component of hallux abducto valgus (HAV), has rarely been discussed and has not been addressed as a component of most HAV corrective procedures. Measurement of a variety of 2-dimensional radiographic angular relationships is thought to be an integral part of the evaluation and surgical treatment of HAV deformity. The intermetatarsal angle (IMA), hallux abductus angle (HAA), proximal articular set angle (PASA), and tibial sesamoid position (TSP) have all been commonly measured in an attempt to define the continuum of the HAV deformity. Although these measurements have been common in practice, we question whether these 2-dimensional parameters can accurately describe the HAV deformity, because they assess the deformity in 2 dimensions and therefore can only accurately assess the deformity in the transverse plane. We know from studying anatomic reports that the first ray deformity associated with HAV is actually a triplane deformity, with components of

the deformity in the transverse, sagittal, and third, or frontal, planes (1–3). Scranton and Rutkowski (1), in a cadaveric study of 35 specimens, measured the valgus rotation (eversion) of the first metatarsal in bunion feet at 14.5° and compared this to a valgus rotation (eversion) in nonbunion feet of 3.1°. Mortier et al (3) undertook a similar study in 2012 in which they showed a statistically significant pronation or valgus position of the metatarsal head in feet with bunion deformities compared with feet without the deformity. Dayton et al (4) reported a case series in which correction of the distal radiographic angles at the first metatarsophalangeal joint (MTPJ), including the PASA and TSP, occurred in association with varus frontal plane rotation of the first metatarsal during metatarsal cuneiform arthrodesis. We believe frontal plane rotation of the first metatarsal to be an integral component of the HAV deformity and believe derotation is necessary for complete deformity correction. The present experiment was undertaken to evaluate the radiographic changes that occur in the first ray during frontal plane rotation of the first metatarsal. Our hypothesis was that the observed measurements for HAA, IMA, PASA, and TSP would change with frontal plane rotation of the first metatarsal and that the measurements will vary with the

Address correspondence to: Paul Dayton, DPM, MS, FACFAS, Unity Point Health, Trinity Regional Medical Center, Des Moines University College of Podiatric Medicine and Surgery, 804 Kenyon Road, Suite 310, Fort Dodge, IA 50501.

E-mail address: [daytonp@me.com](mailto:daytonp@me.com) (P. Dayton).

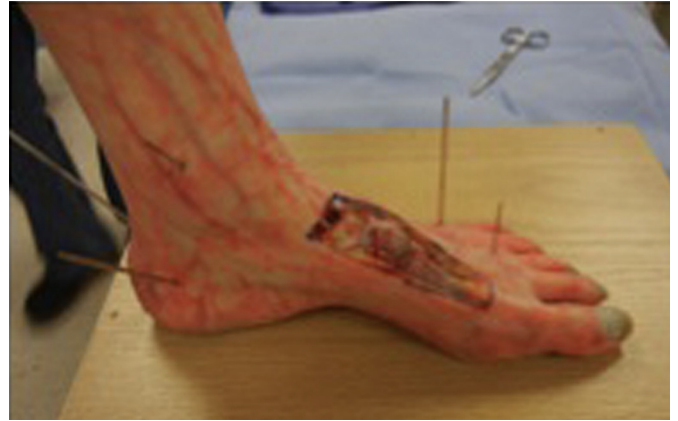

**Fig. 1.** The joint and limb stabilization with Kirschner wires through the ankle, subtalar joint, midtarsal joint, and into the stabilization platform to limit all unwanted movement.

magnitude and direction of frontal plane rotation applied to the first metatarsal.

#### Materials and Methods

Five fresh-frozen cadaveric specimens were obtained for the purposes of the present study. All 5 of the specimens were obtained from female cadavers. Three were left feet and two were right feet. The mean age at death was 86 years old. Each specimen was examined clinically to determine whether any gross deformities were present, including HAV deformity. No gross forefoot or midfoot deformities were noted in any of the specimens. Each specimen was placed in the neutral position and fixated to a stabilizing block with multiple Kirschner wires: through the ankle joint to

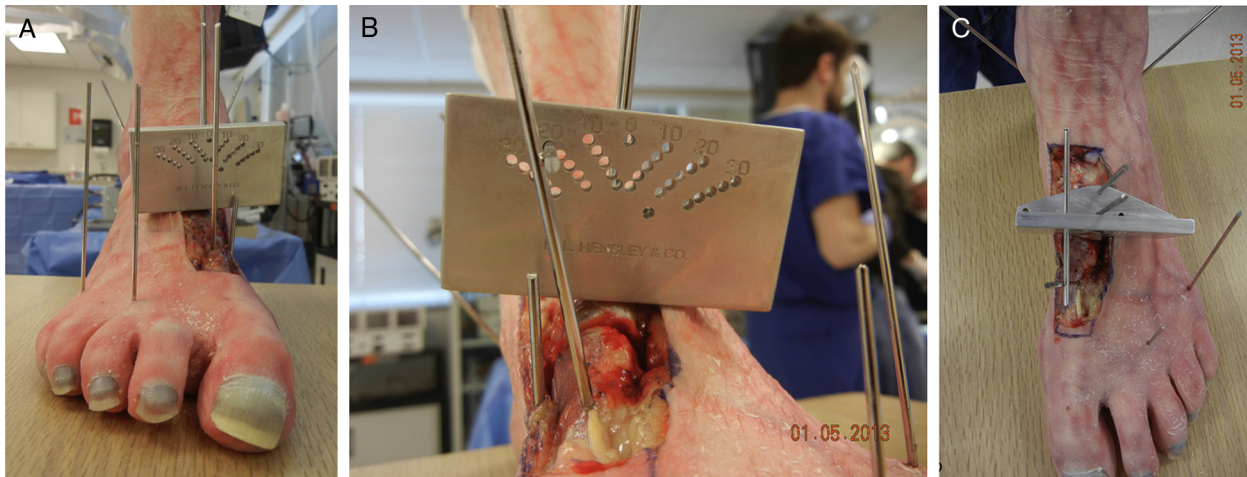

**Fig. 2.** Dissection of the metatarsal-cuneiform joint release with no bone resection.

stabilize the ankle and subtalar joint, through the calcaneal-cuboid joint, through the talonavicular joint, and through the third and fifth metatarsals (Fig. 1). Rotational measurements were obtained using a custom protractor device created by the primary author (P.D.) to show differences in the rotational angles. The device was designed to be fixed with 2 pins to the specimen at the first-cuneiform and allow independent rotation of the first metatarsal while maintaining the position of the measuring device. An additional pin was fixed to the first metatarsal before joint release and calibrated to the 0° position (Fig. 2). Once all the wires were in place and the foot had been securely stabilized, the first metatarsal-cuneiform joint was released by sharp soft tissue dissection and rotated and then held in position with pins through the device (Fig. 3). No bone was resected, and no release was done at the distal MTPJ. Radiographs were then taken of each cadaveric specimen using a standard radiographic technique (Fig. 4), with the first metatarsal set at 0° rotation (neutral position), 10°, 20°, and 30° of varus rotation (inversion), and 10°, 20°, and 30° of valgus rotation (eversion) (Figs. 4 and 5). Seven radiographs from each specimen were then randomized and blinded before measurement of the HAA, PASA, TSP, and IMA. Four of us (P.D., M.F., J.H., M.K.) measured each radiograph, and the measurements were averaged to calculate a mean for each of the characteristics measured. The measurements taken by each investigator were done using the standard methods described by Gerbert (5). The mean value of each characteristic was used in the statistical analysis using a mixed linear model.

#### Results

The bone quality of 1 of the specimens was not adequate to withstand the rotational forces on the pin; therefore, the amount of rotation could not be accurately measured. The data from that



**Fig. 3.** (A) Joint rotation calibrated at 0° before metatarsal-cuneiform joint release and pin fixation. (B) Method of rotation using measuring device. In this instance, the rotation was 20° in valgus. (C) The method of measurement of rotation with custom-measuring device.

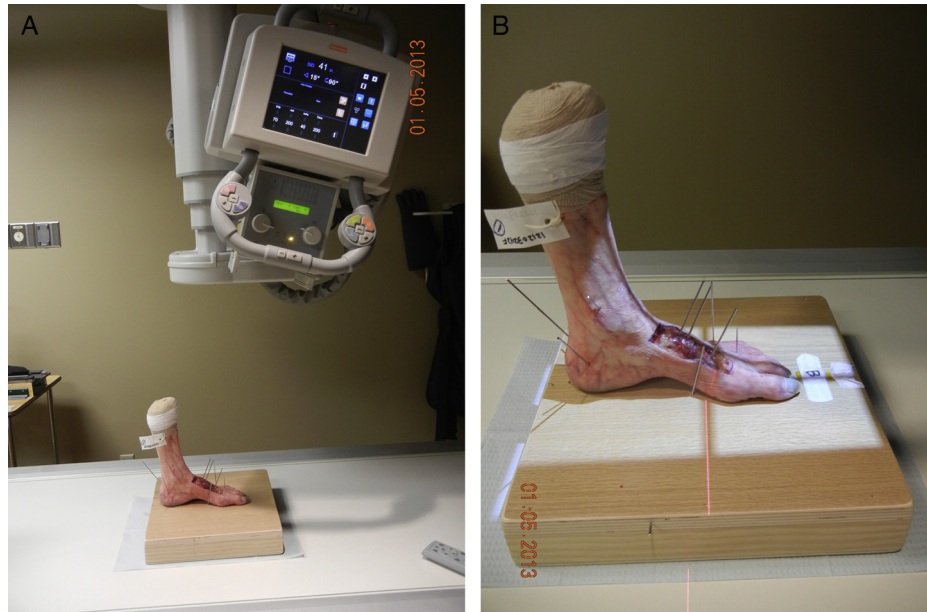

Fig. 4. A standard radiographic technique was used for each specimen.

specimen was discarded. Of the 4 specimens included in the analysis, none had had a pre-existing HAV deformity or gross forefoot or midfoot deformity. The raw data, consisting of the mean measurements for PASA, IMA, HAA, and TSP for each point of valgus and varus rotation, are listed in Table 1. The data were analyzed using a mixed linear model to compare the change in each measurement over the range of valgus and varus rotation. The change in the TSP was significant in both valgus and varus rotations ( $p = .0004$  and  $p = .028$ , respectively), showing that an increase in valgus rotation results in an increase in the TSP and an increase in varus rotation results in a decrease in the TSP. Changes in the IMA were significant compared with valgus rotation ( $p = .028$ ), showing that as the valgus rotation increased, the IMA also increased. However, when the IMA was compared with the varus rotation, the correlation was not significant ( $p = .18$ ). When the mixed linear model was applied to the PASA and HAA measurements with metatarsal rotation, our results showed positive trends, but the differences were not statistically significant (Table 2).

## Discussion

We have previously discussed observations of varus frontal plane rotation of the first ray resulting in a reduction of the angular and other radiographic findings routinely measured when analyzing a bunion deformity (4). In a clinical case series, the following changes were noted after Lapidus arthrodesis with varus rotation or inversion of the first metatarsal: IMA of  $10.1^\circ$ , HAA of  $17.8^\circ$ , PASA of  $18.7^\circ$ ,

TSP improvement of  $3.8^\circ$ . Also, a consistent valgus, or everted, position of the first metatarsal was noted as a component of the HAV deformity in our patient population and was corrected by varus rotation or inversion of the metatarsal. This research was performed to further analyze the contribution of frontal plane rotation of the first metatarsal to changes in the IMA, HAA, PASA, and TSP. The statistical analysis showed that TSP was the 1 parameter that correlated closely with rotation of the first metatarsal. Ramdass and Meyr (6), in 2010, reported a study that had measured the sesamoid position using a variety of methods, both preoperatively and post-operatively. They compared the TSP to the IMA and HAA and to the second metatarsal head, which was considered a stationary point. Ramdass and Meyr (6) found that although the TSP change correlated directly with the IMA, the tibial sesamoid to second metatarsal distance did not change. They noted that the angle between the sesamoids and the weight bearing surface of the metatarsal had decreased. Considering these data, one can conclude that the radiographic appearance of the sesamoids is a product of movement of the metatarsal and not actual changes in the sesamoid position. The correlation of an increased TSP with eversion or valgus metatarsal rotation and a decreased TSP with varus or inversion rotation was directly observed throughout our range of measurements. We believe this also supports the idea that frontal plane rotation of the first ray or the “third plane of deformity” is an important component of HAV and that rotation should be considered in the surgical approach to HAV and metatarsus primus adductus to obtain anatomic alignment.

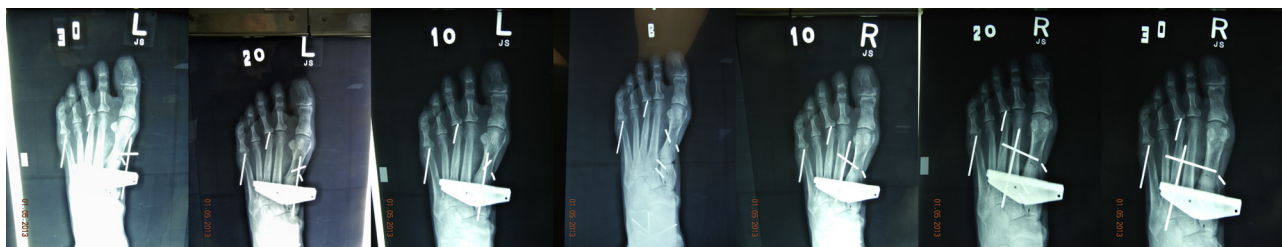

Fig. 5. Radiographic images showing rotation from the original baseline image (B),  $10^\circ$  valgus (10 L),  $20^\circ$  valgus (20 L),  $30^\circ$  valgus (30 L),  $10^\circ$  varus (10 R),  $20^\circ$  varus (20 R), and  $30^\circ$  varus (30 R).



**Table 1**  
Average measurements for each specimen relative to magnitude of frontal plane rotation

Specimen	30° Valgus	20° Valgus	10° Valgus	Neutral	10° Varus	20° Varus	30° Varus
1							
PASA (°)	4.75	7.25	7.25	7.125	4	6	8.75
IMA (°)	11.5	11.25	10	8.75	7.5	6.75	8.75
HAA (°)	11.25	11.5	10.75	12	12.25	11.75	13.5
TSP	5.25	4.75	4.5	3.5	3	1.75	1
2							
PASA (°)	3	4.75	2.75	2	4.5	1.75	3
IMA (°)	11.5	11.75	10.5	10.75	9.25	6.75	6.75
HAA (°)	9	10	6.25	7.5	9	9	11.75
TSP	5.5	3.75	4.25	4	3	2.25	1.5
3							
PASA (°)	6.5	8	7.5	7	5.75	10.25	6.75
IMA (°)	6.75	6.75	7.5	6.25	5.25	6.25	6.75
HAA (°)	9	10.25	12.75	12.5	11	16.75	11.75
TSP	4.75	4.5	4	1.75	1	1.25	1
4							
PASA (°)	8.5	7	6.25	3	5.25	3.5	2.5
IMA (°)	9	10	10	5.75	5	5	4.5
HAA (°)	9.5	11.5	10.75	7.75	10	8	9
TSP	5.5	5.25	4.75	2.75	1.75	1.25	1

Abbreviations: HAA, hallux abductus angle; IMA, intermetatarsal angle; PASA, proximal articular set angle; TSP, tibial sesamoid position.

The concept of frontal plane rotation altering the observed TSP position also raises an important question regarding correction of the TSP intraoperatively. We question whether sesamoid release and repositioning maneuvers, such as capsulorrhaphy and tendon transfer, which have been recommended as a component of many bunion operations, are effective in the long term, and, therefore, we question whether these are necessary. We agree that in the intraoperative setting, lateral release of the sesamoids and medial capsular plication can improve the visual position of the sesamoids under the metatarsal. However, if frontal plane rotation is the fixed component of the malposition, these procedures would likely cause additional joint misalignment and not permanent correction. Additionally, most surgeons would agree that in a number of cases, the correction of the sesamoid position obtained through release and plication will not be maintained in the long term. It has been well documented that failure to obtain TSP reduction has often been related to recurrence of an HAV deformity (7,8). The recommendation that a medial capsule plication be implemented to draw the sesamoid apparatus back underneath the first metatarsal head to realign the pull of the flexor hallucis brevis tendon has been compelling, because the change in position will be immediately visible. However, as previously stated, Ramdass and Meyr (6), in 2010, and Agrawal et al (9), in 2011, have shown that the sesamoid apparatus never actually moves in the transverse plane when the distance was measured against the second metatarsal. These facts would support the argument against the need to pull the sesamoid apparatus back under the first metatarsal and would instead argue for the need to move the first metatarsal back over the sesamoid apparatus. The vast ligamentous attachment of the sesamoids to the first and second metatarsal and the proximal phalanx, in reality, will prevent sesamoid repositioning (8). This might appear contradictory; however, if we accept that, as a part of the HAV deformity, the first

**Table 2**  
Results summary as *p* values of each measurement in relation to direction of change

Measurements	Valgus Rotation ( <i>p</i> value)	Varus Rotation ( <i>p</i> value)
PASA	.55	.63
IMA	.028	.18
HAA	.99	.15
TSP	.0004	.028

Abbreviations: HAA, hallux abductus angle; IMA, intermetatarsal angle; PASA, proximal articular set angle; TSP, tibial sesamoid position.

metatarsal everts into a valgus position and the sesamoids are still anatomically affixed, we can then explain the visual change in position with rotation. As the metatarsal everts, the shaft of the bone also deviates medially; however, the sesamoids remain in a position roughly equal distance from the second metatarsal, and they now appear to be more lateral to the first metatarsal. This would account for the consistently measured distance with rotation of the first metatarsal (6). When the metatarsal has been derotated as a part of the bunion procedure, the sesamoids visually, and in reality, return to their proper place under the first metatarsal.

Although we measured the distal joint changes with metatarsal rotation, we could not state with any certainty at which level the rotation occurs in the patients with HAV. The rotation associated with HAV can occur at the first metatarsal cuneiform joint, the navicular and intercuneiform joints, or at another level. Our model used a point of freedom at the metatarsal cuneiform joint, but this certainly does not prove this to be the level of actual deformity in the case of HAV and MPA. Our specimens did not have a pre-existing HAV deformity; therefore, we cannot draw a conclusion regarding the actual level of rotational deformity. We believe that the specimens not having pre-existing HAV was also the reason the other radiographic measurements did not correlate as closely with the rotation that we have observed in other patients with HAV (4).

With the exception of the change in the IMA, the other measurement changes were not statistically significant. The change in IMA was significant compared with valgus rotation ( $p = .028$ ), showing that as the valgus rotation increased, the IMA also increased. This might also correlate with the position of the sesamoid apparatus. In our study, when the first metatarsal was everted, the sesamoid bones appeared to have moved from the plantar aspect of the bone to what would appear now to be the lateral aspect of the metatarsal. However, they were still in their appropriate anatomic position, not having been released from the MTPJ. In the patient with HAV, the rotation will change the direction of the pull of the flexor hallucis brevis from plantar flexion at the first MTPJ to abduction at the first MTPJ. Derotation of the metatarsal will place the sesamoids back in their proper plantar location and also allow the flexor tendon to pull in its proper alignment.

A trend was seen toward a statistically significant correlation of rotation with HAA and PASA; however, a distinct correlation could not be made in the present data set. Perhaps with a larger sample size, the contribution of rotation could be determined, and, potentially, other

correlations could be found. As noted previously, the specimens did not have pre-existing deformity, and we could not conclude how this fact might have changed our observations. Additional studies are needed of both deformed and nondeformed feet to assess the radiographic changes that occur with frontal plane rotation of the first metatarsal.

From the information obtained in the present cadaver experiment, we can conclude that changes in the TSP can be directly correlated with rotation of the first metatarsal. Valgus rotation of the metatarsal increased both the TSP and IMA, and varus rotation consistently decreased the TSP. From this information, and an analysis of previous research, we believe frontal plane rotation of the first ray needs to be addressed for complete anatomic correction of a hallux valgus pathologic entity. Additional studies are needed to further understand the role that frontal plane rotation might play in bunion pathologic entities.

### Acknowledgments

We would like to thank the Research and Grants Committee of Des Moines University for their generous grant support of this work through the Iowa Osteopathic Educational Research Fund. We would

also like to thank Karin Nowicki, RN, and Jean Schuster, RT, of Des Moines University for their assistance in this project.

### References

1. Scranton PE, Rutkowski R. Anatomic variations in the first ray. Part 1: anatomic aspects related to bunion surgery. *Clin Orthop Rel Res* 151:244–255, 1980.
2. Grode SE, McCarthy DJ. The anatomical implications of hallux abducto valgus: a cryomicrotomic study. *J Am Podiatr Med Assoc* 70:539–551, 1980.
3. Mortier JP, Bernard JL, Maestro M. Axial rotation of the first metatarsal head in a normal population and hallux valgus patients. *Orthop Traumatol Surg Res* 98:677–683, 2012.
4. Dayton P, Feilmeier M, Kauwe M, Hirschi J. Relationship of frontal plane rotation of first metatarsal to proximal articular set angle and hallux alignment in patients undergoing tarsometatarsal arthrodesis for hallux abducto valgus: a case series and critical review of the literature. *J Foot Ankle Surg* 52:348–354, 2013.
5. *Textbook of Bunion Surgery*, edited by J Gerbert, WB Saunders, New York, 2001.
6. Ramdass R, Meyr AJ. The multiplanar effect on first metatarsal osteotomy on sesamoid position. *J Foot Ankle Surg* 49:63–67, 2010.
7. Okuda R, Kinoshita M, Yasuda T, Jotoku T, Kitano N, Shima H. Postoperative incomplete reduction of the sesamoids as a risk factor for recurrence of hallux valgus. *J Bone Joint Surg* 91:1637–1645, 2009.
8. Wooster M, Davies B, Catanzariti A. Effect of tibial sesamoid position on long term results of HAV surgery. *J Foot Surg* 29:543–550, 1990.
9. Agrawal Y, Desai A, Mehta J. Lateral sesamoid position in hallux valgus: correlation with the conventional radiological assessment. *Foot Ankle Surg* 17:308–311, 2011.